

MUNI
MED

FAKULTNÍ
NEMOCNICE
U SV. ANNY
V BRNĚ



Senec 2021

Michal Hendrych

Pacient

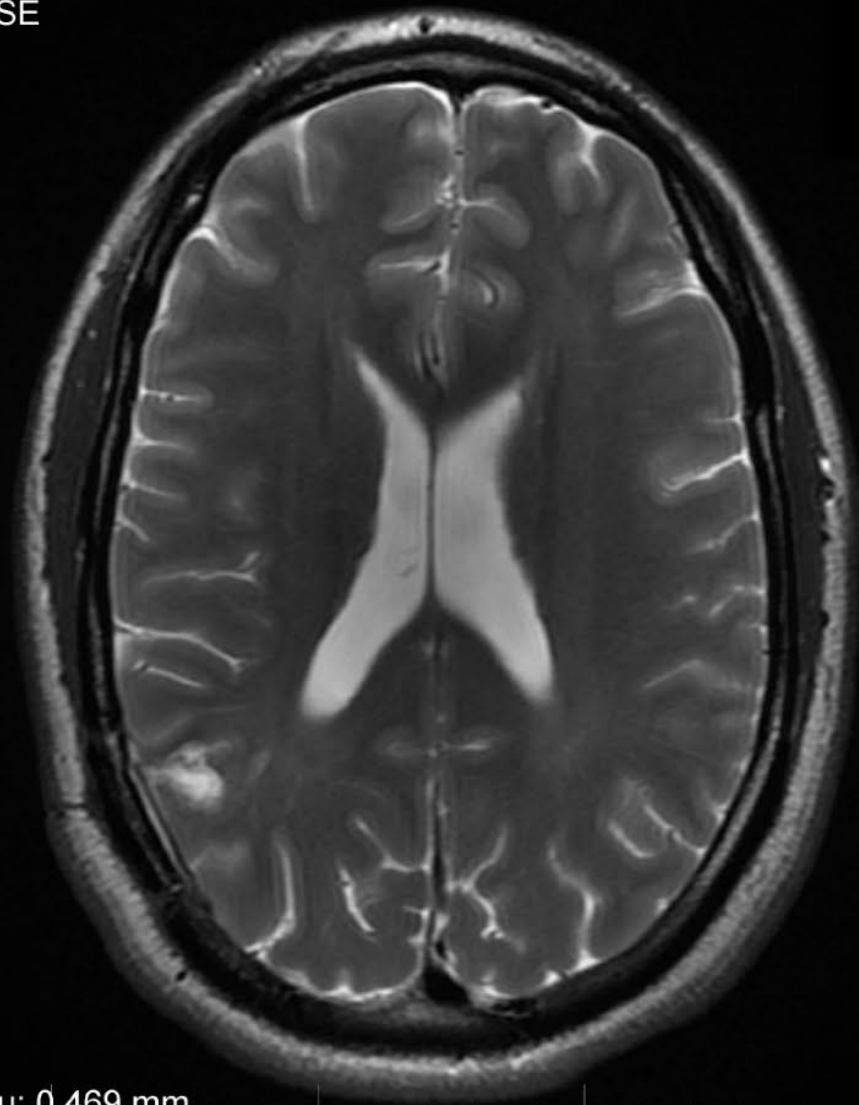
- 27- letý muž s farmakorezistentní epilepsií trvající 4 roky
- FBTCS – fokální záchvaty přecházející do bilaterálního tonicko-klonického záchvatu
- Pozáchvatová zmatenost, spavost, agitovanost a afázie.

MR/3/40
Axiální
AX T2&PD FSE

A

A

R



ET: 10
TR: 4304.0
TE: 111.6
Velikost pixelu: 0.469 mm
Pozice: -2.1 mm
W: 8463 L: 4231

P

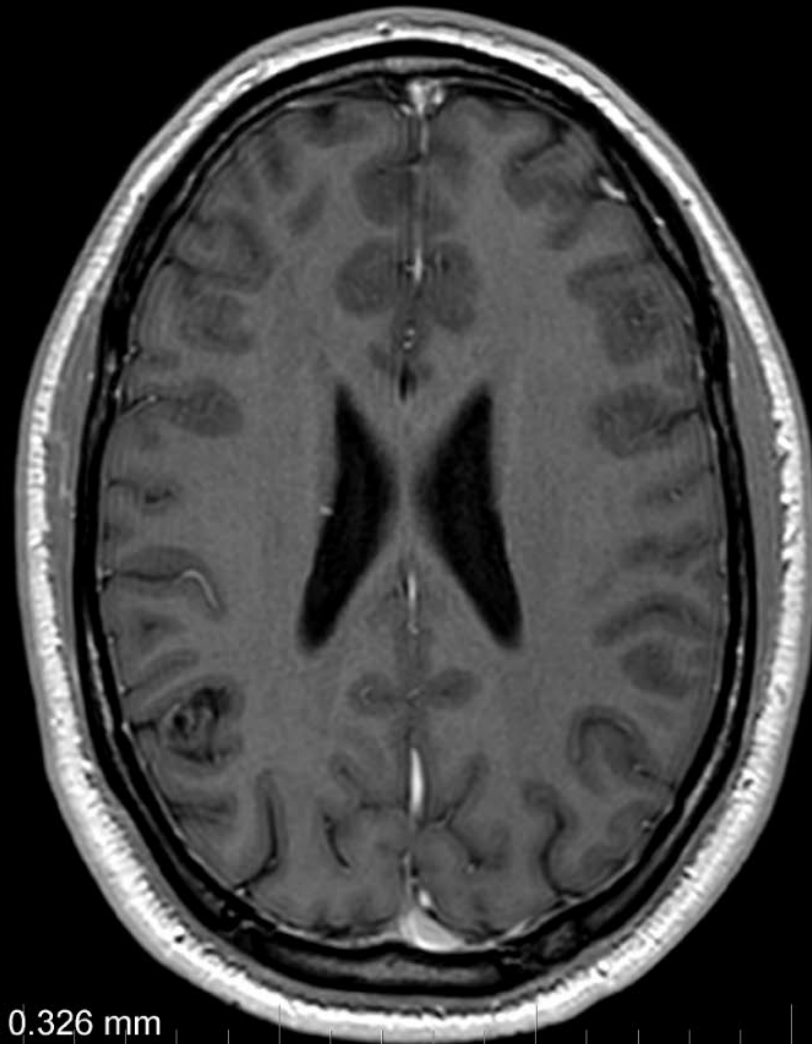
DFOV: 24.00 x 24.00cm W: 823 L: 473

MR/601/90
Axiální
KL - T1_3D
HEAD

A

B

LR



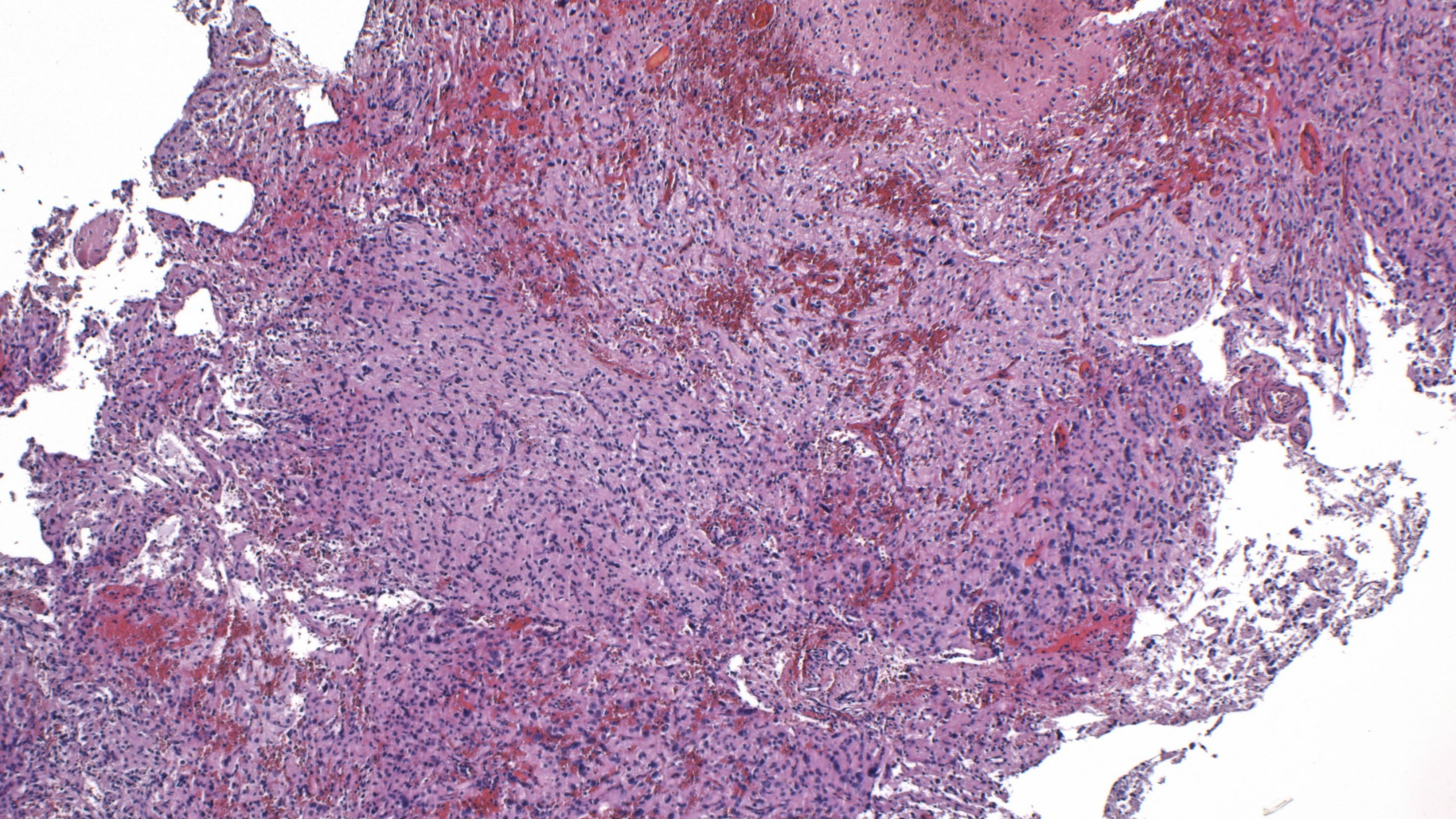
ET: 1
TR: 25.0
TE: 4.5
Velikost pixelu: 0.326 mm
Pozice: 41.6 mm

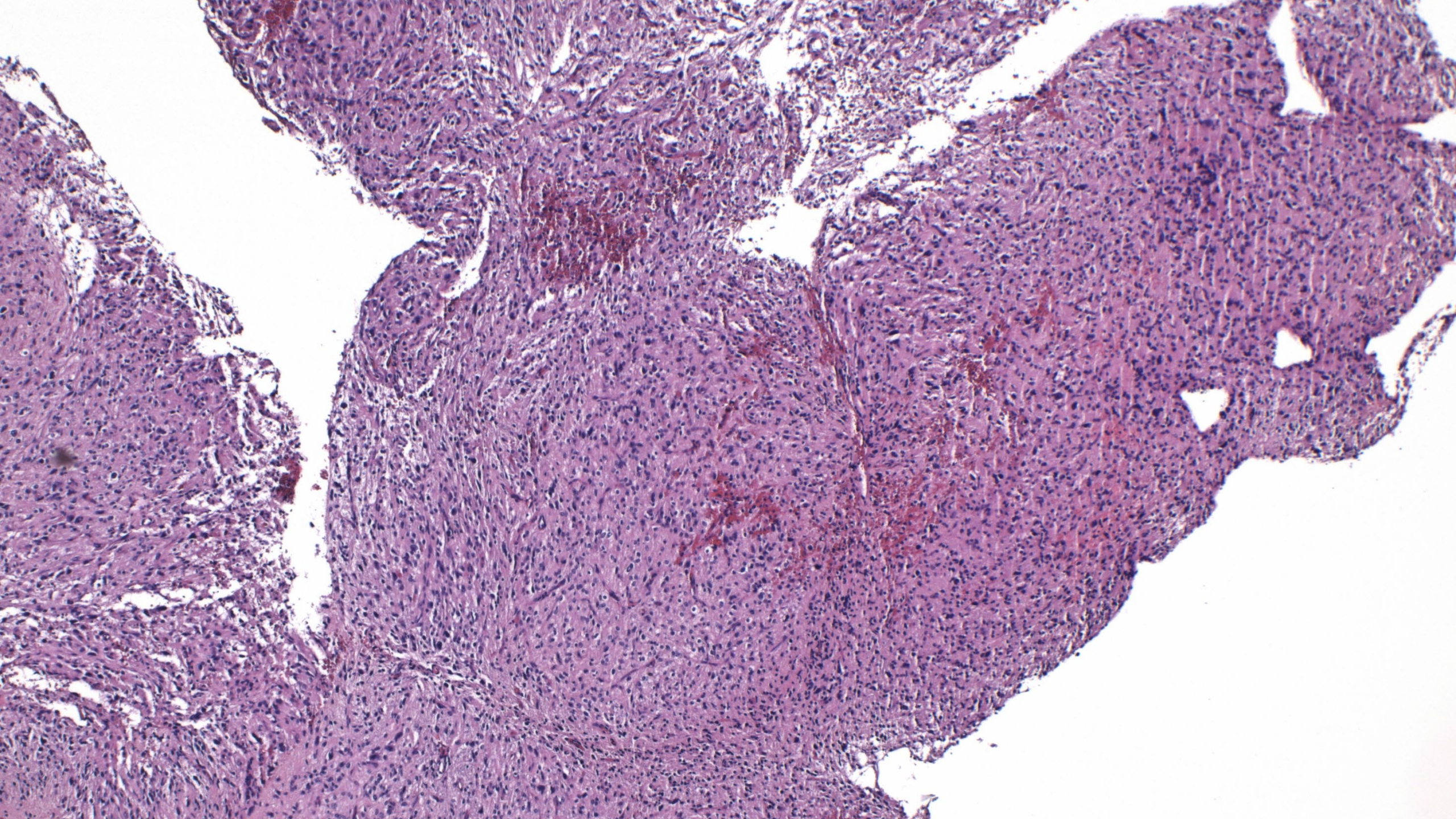
P

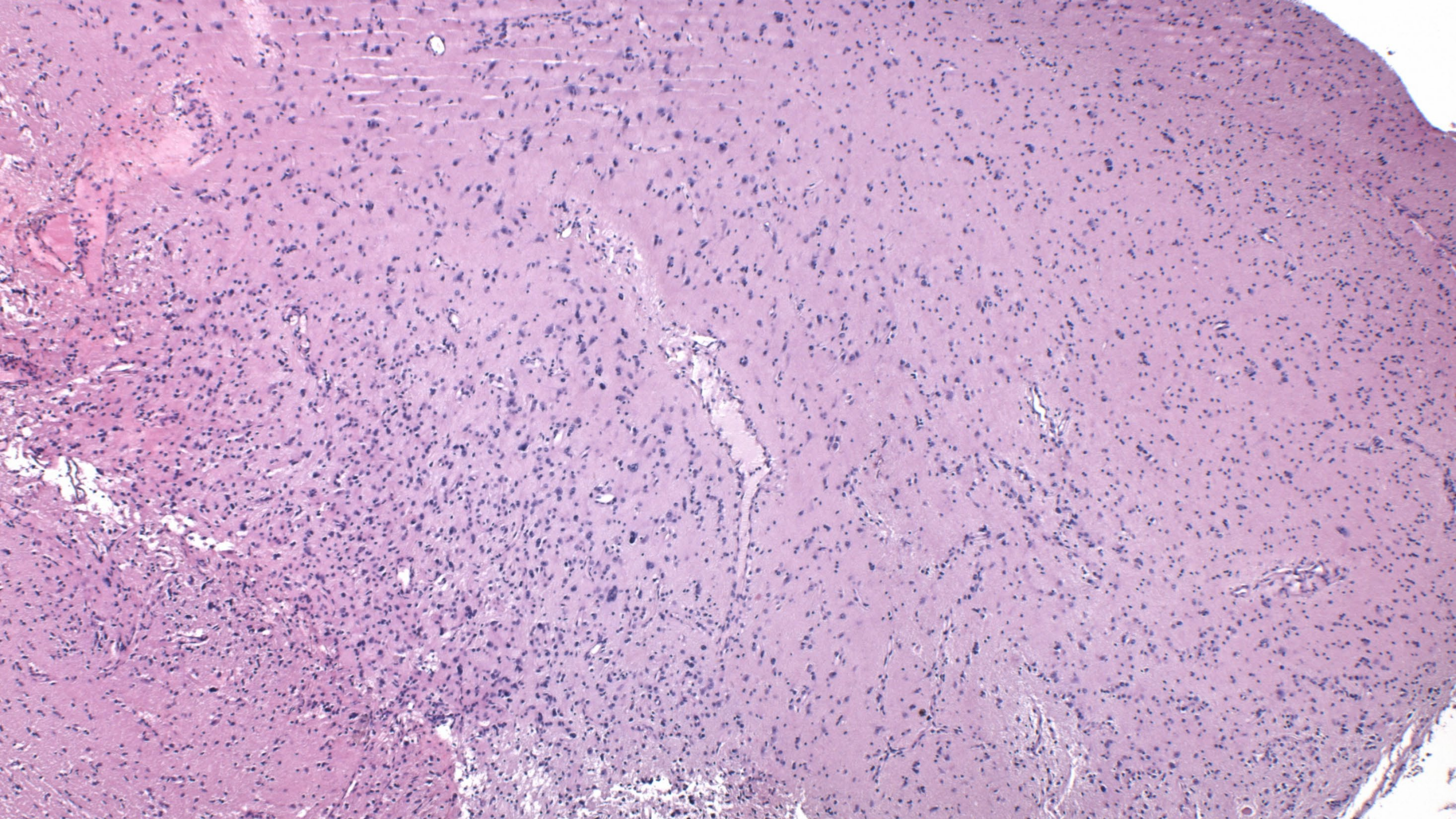
DFOV: 25.00 x 25.00cm

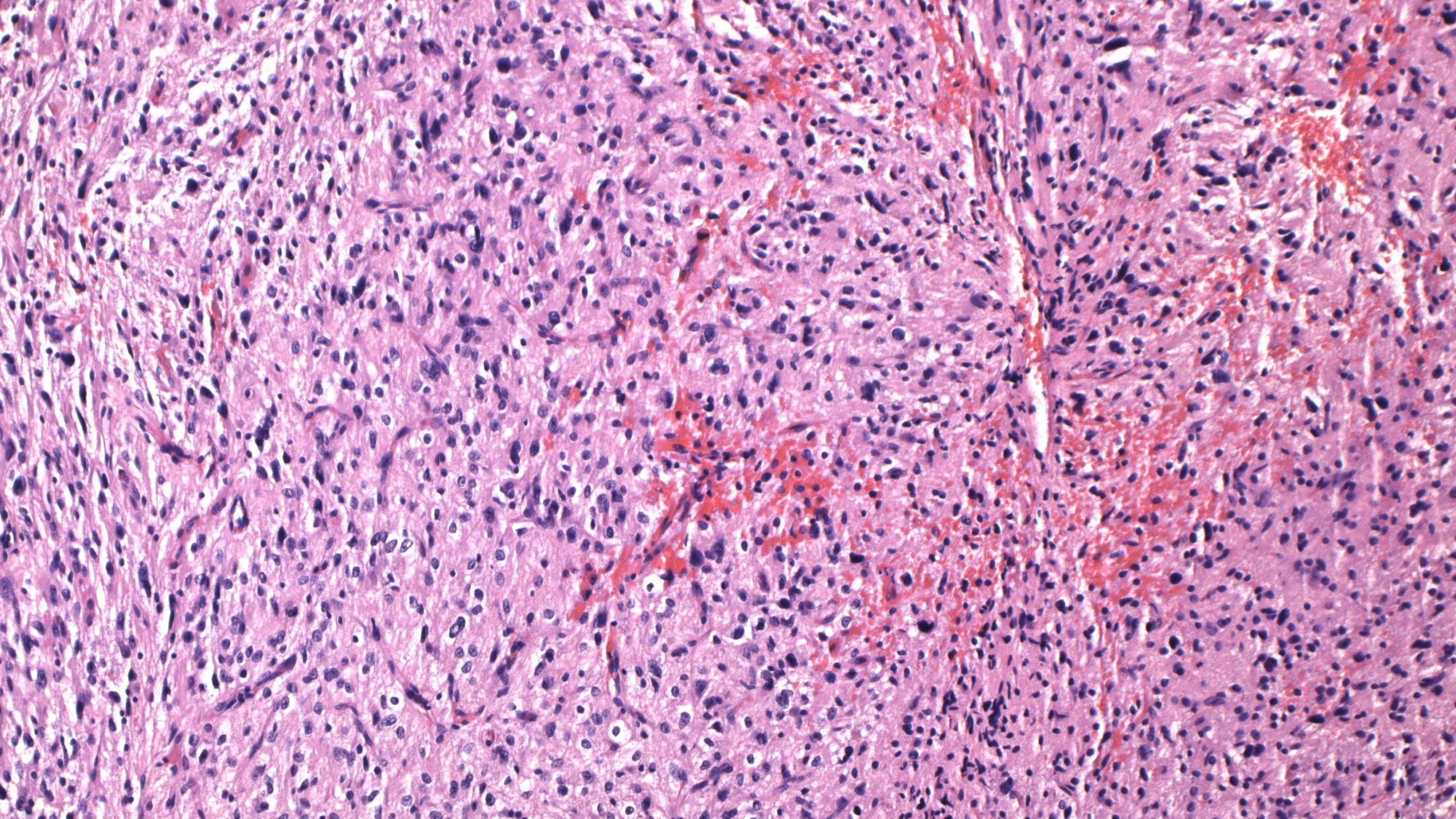
Peroperační nález

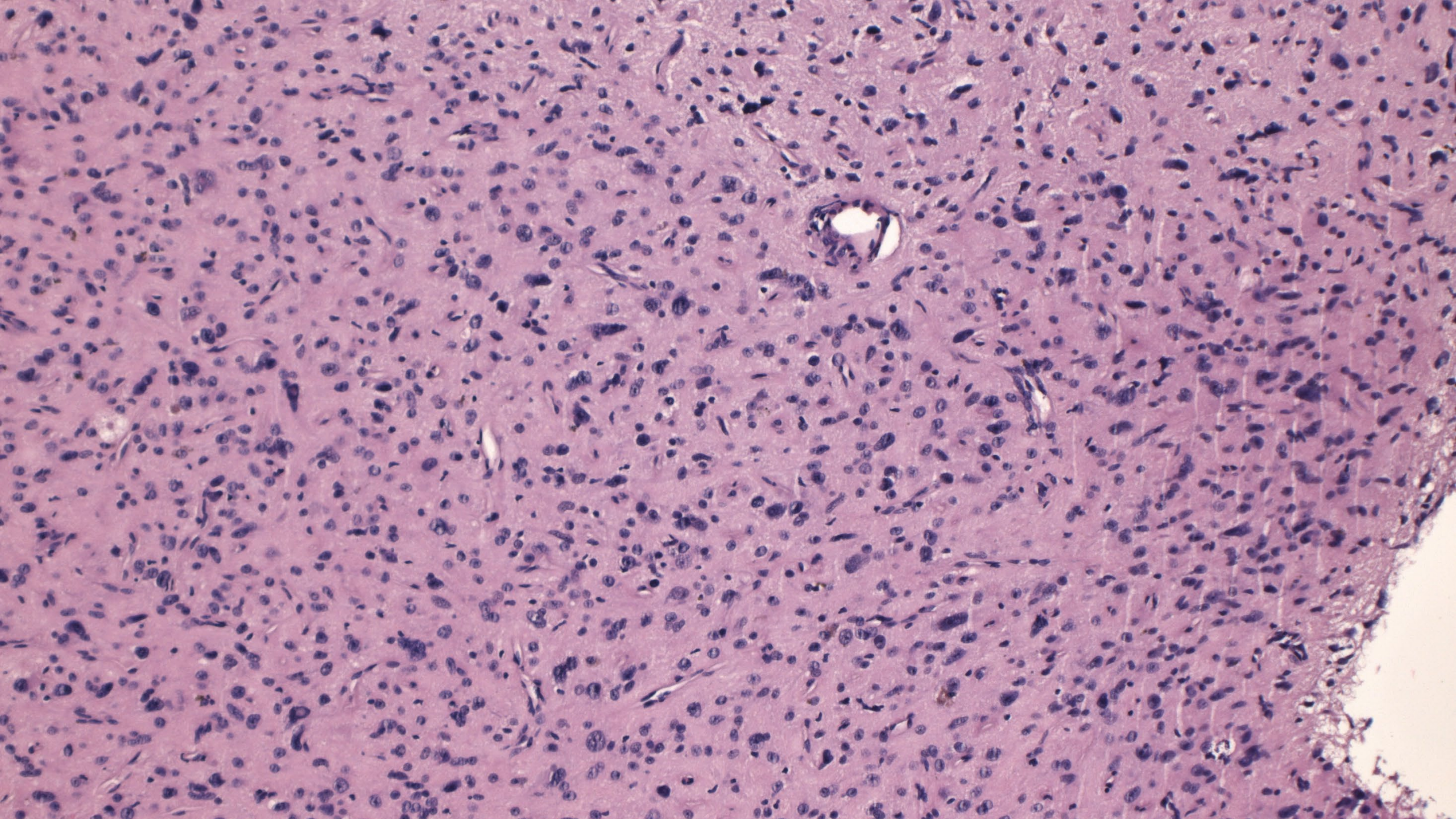
- Ohraničená léze šedo-růžové barvy subkortikálně uložena
- Gross-total resekce
- Elektrokortikografie z postresekční dutiny zobrazující normální elektrickou aktivitu.

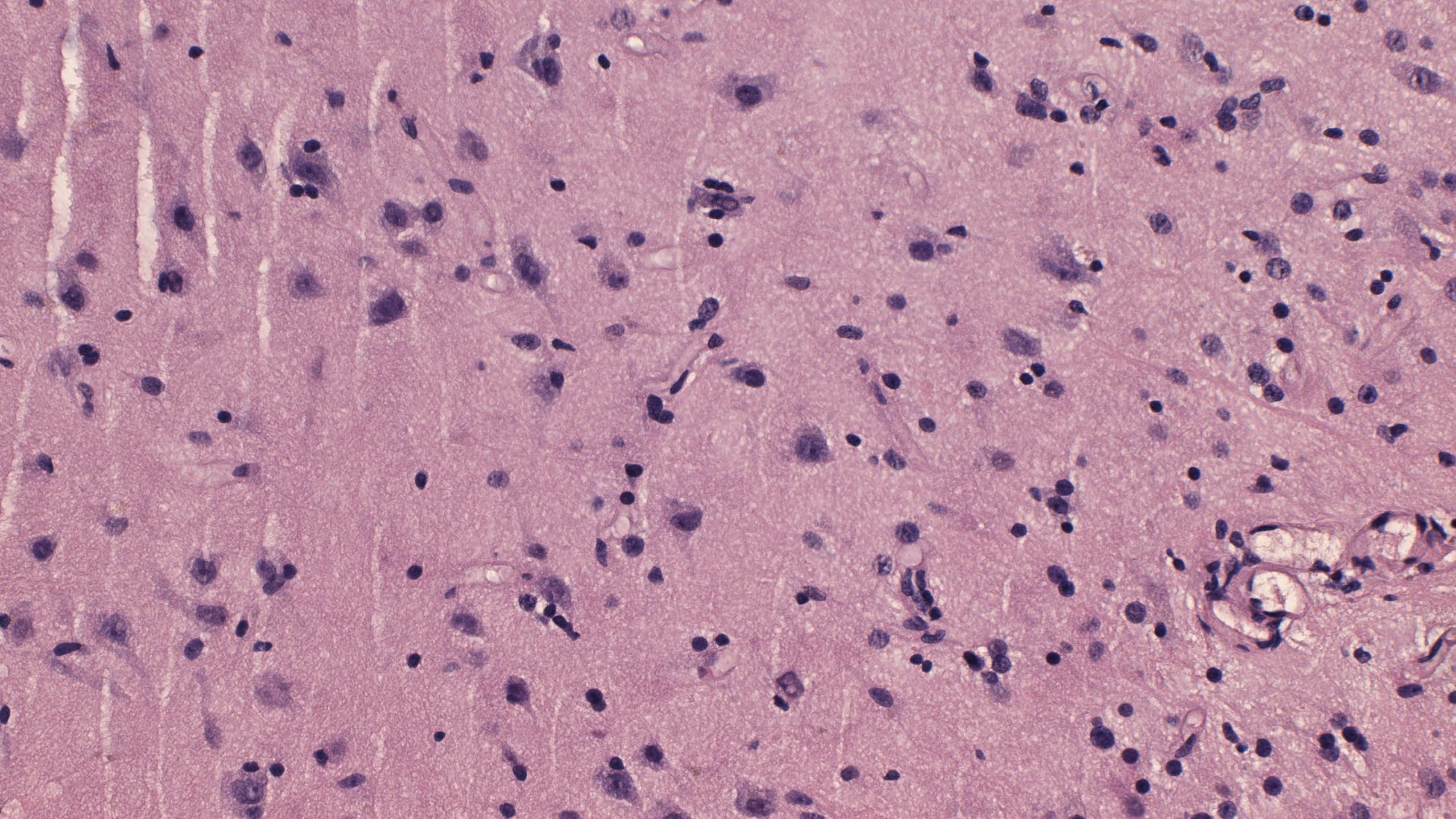


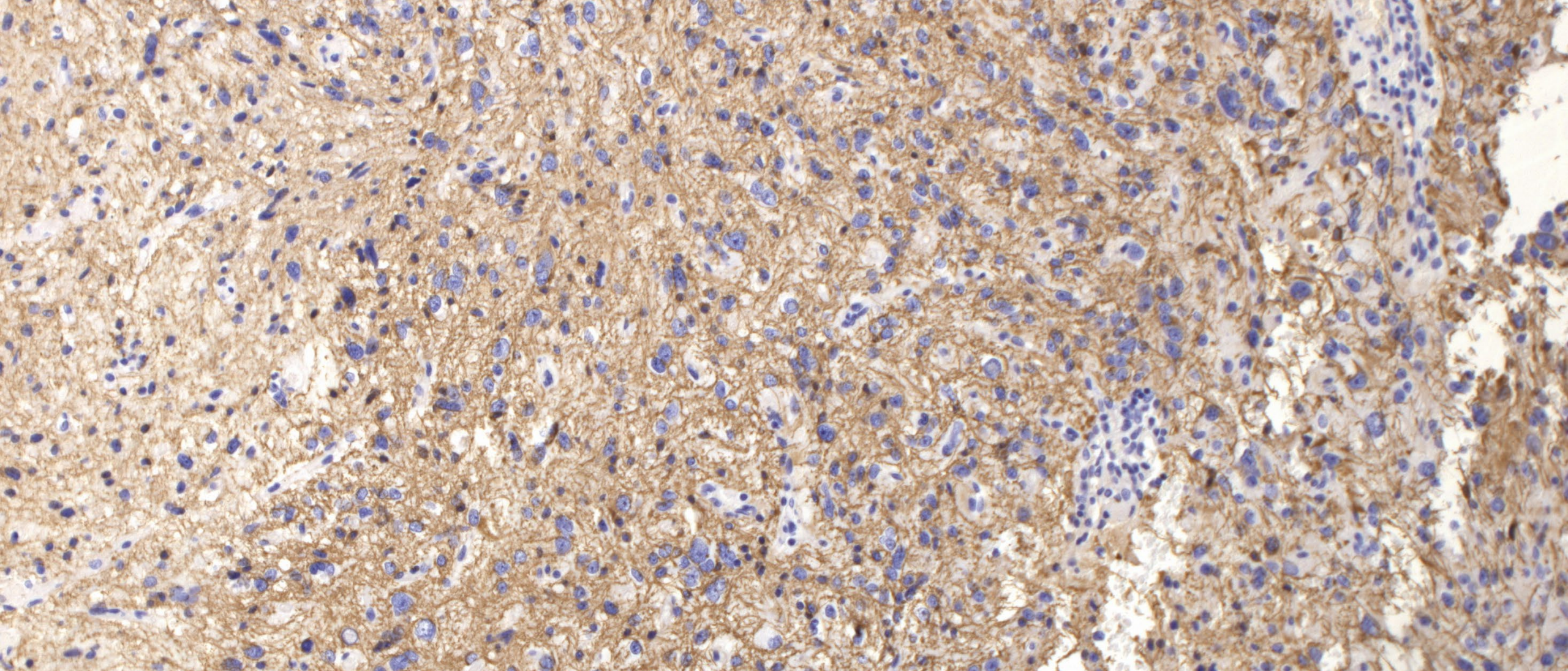




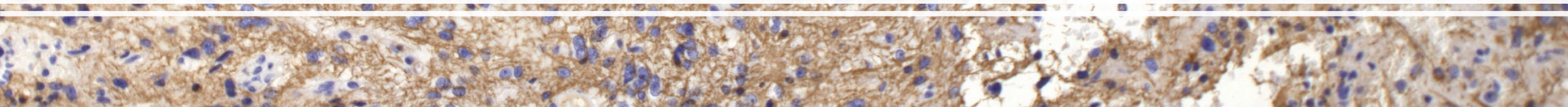


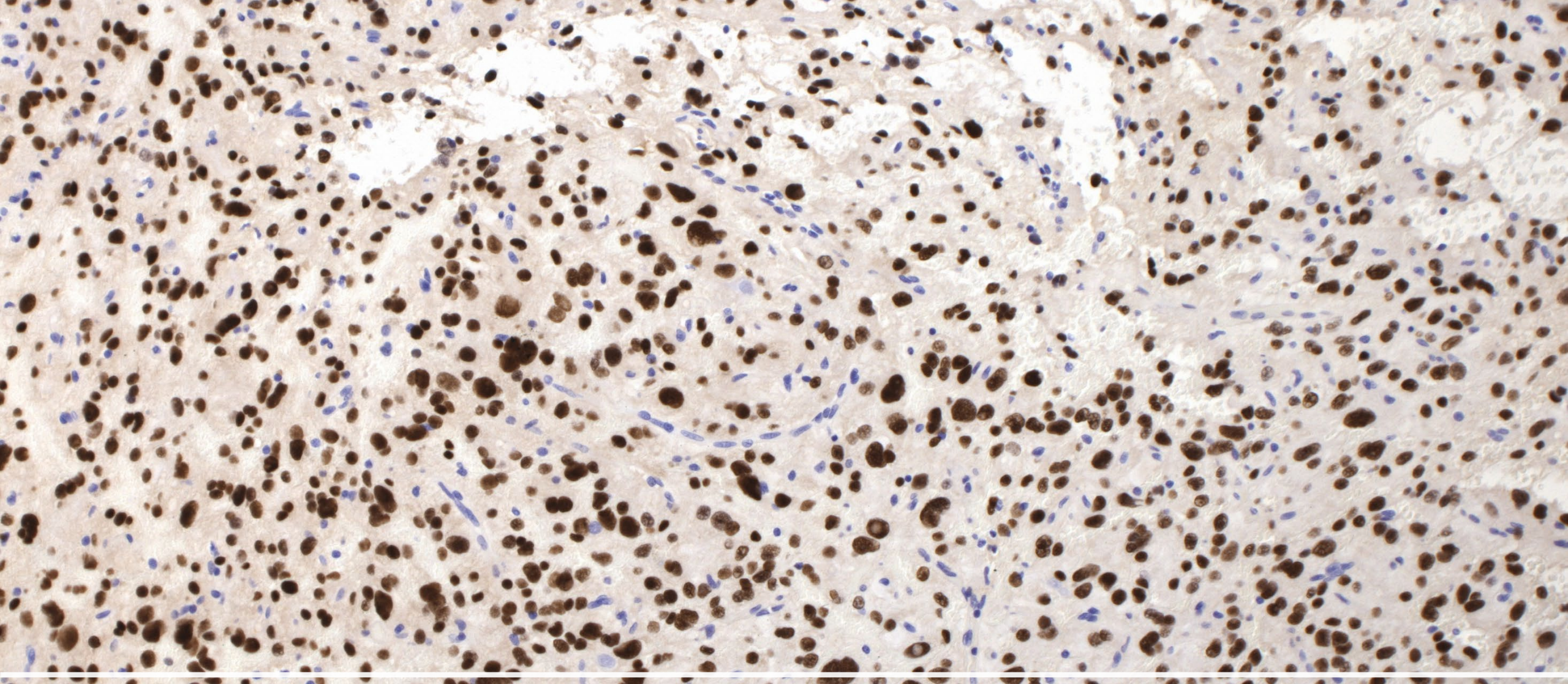




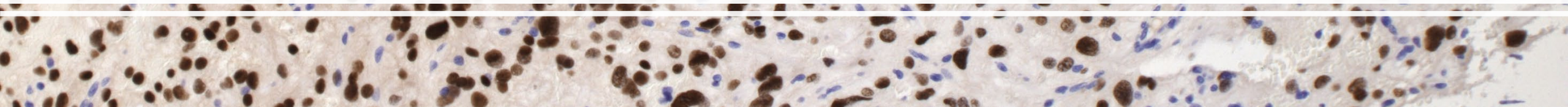


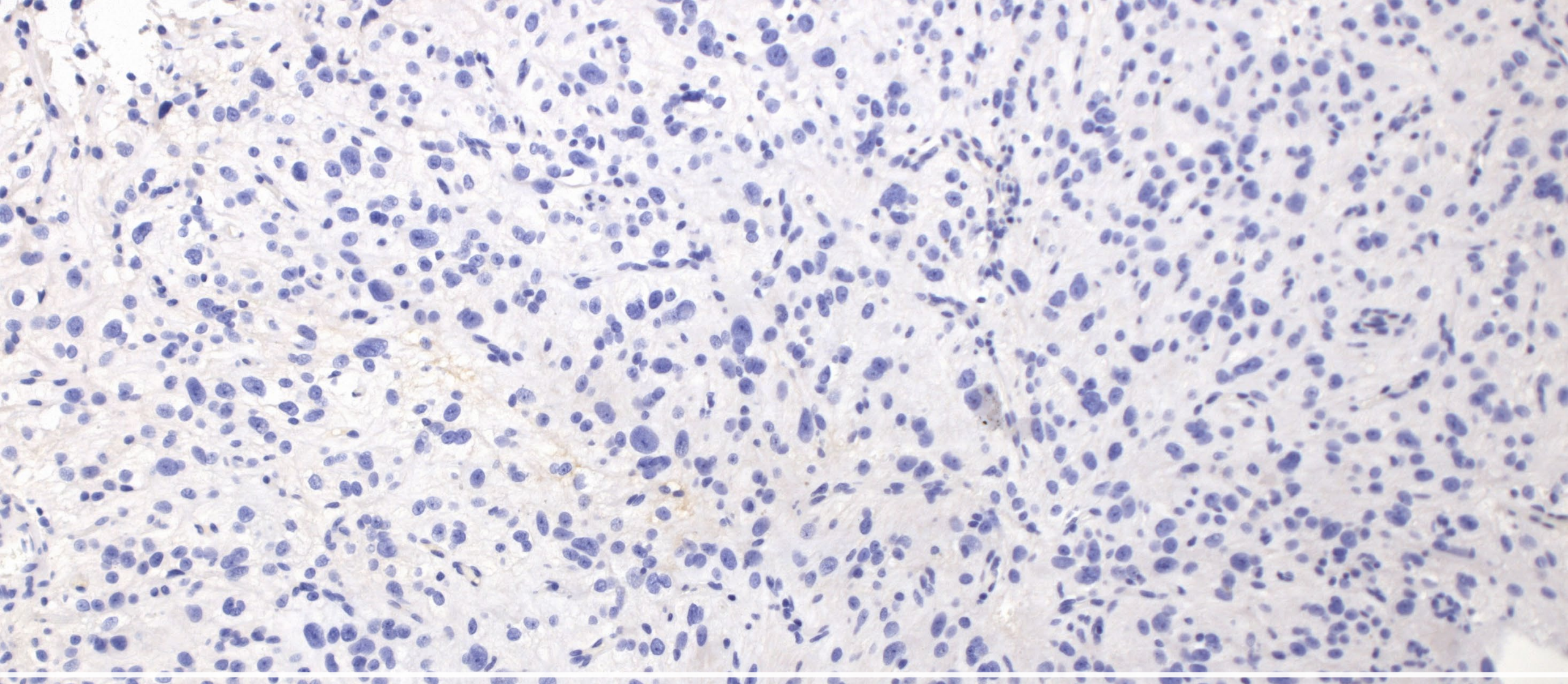
GFAP



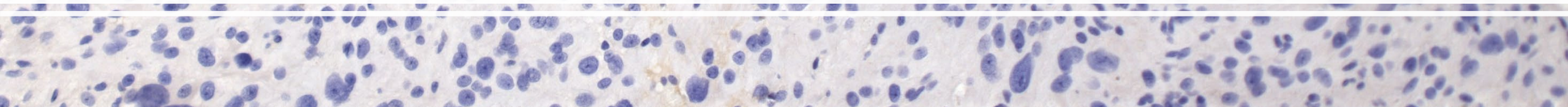


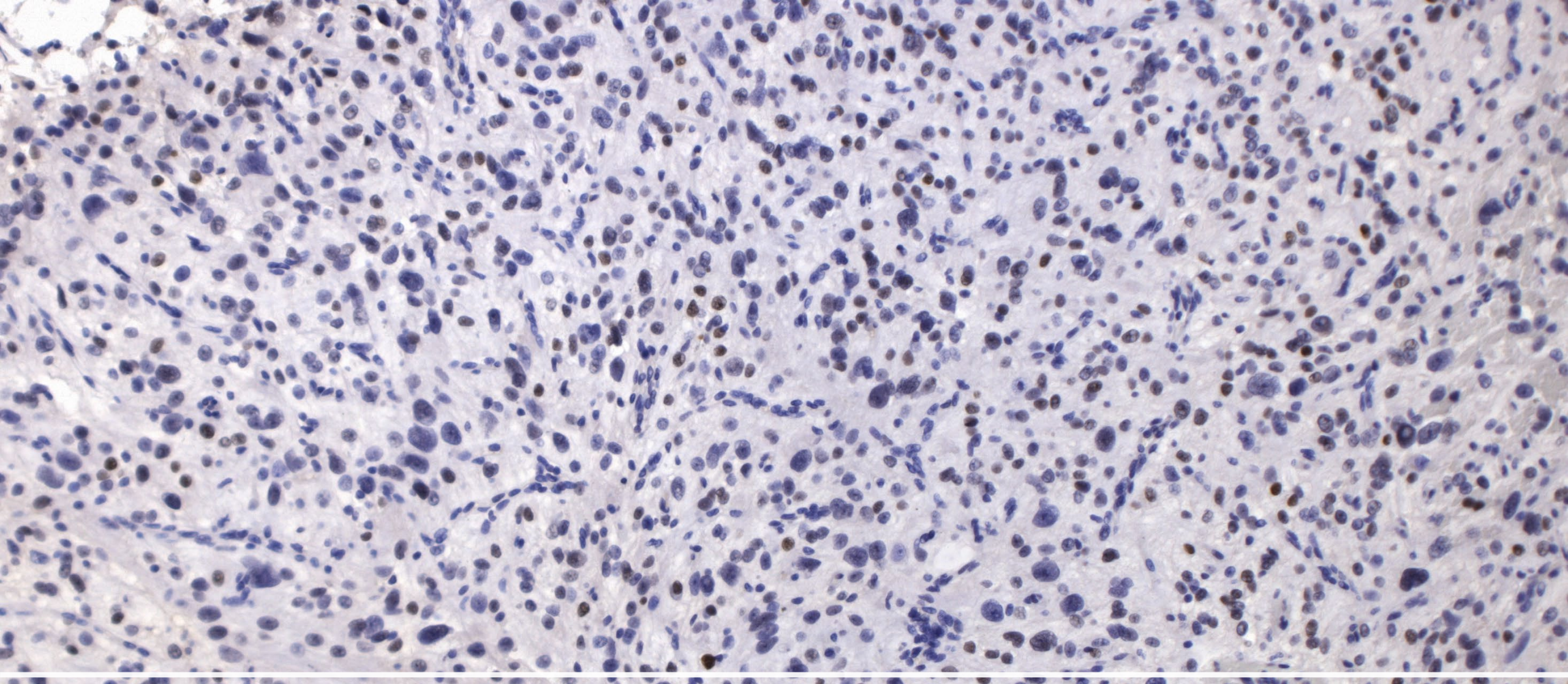
OLIG2



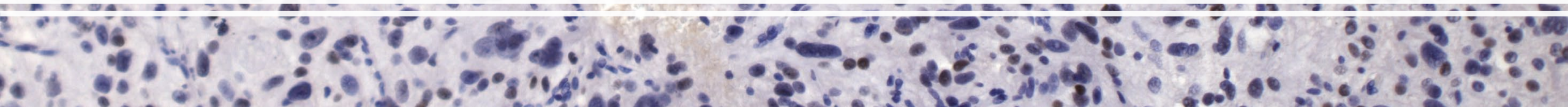


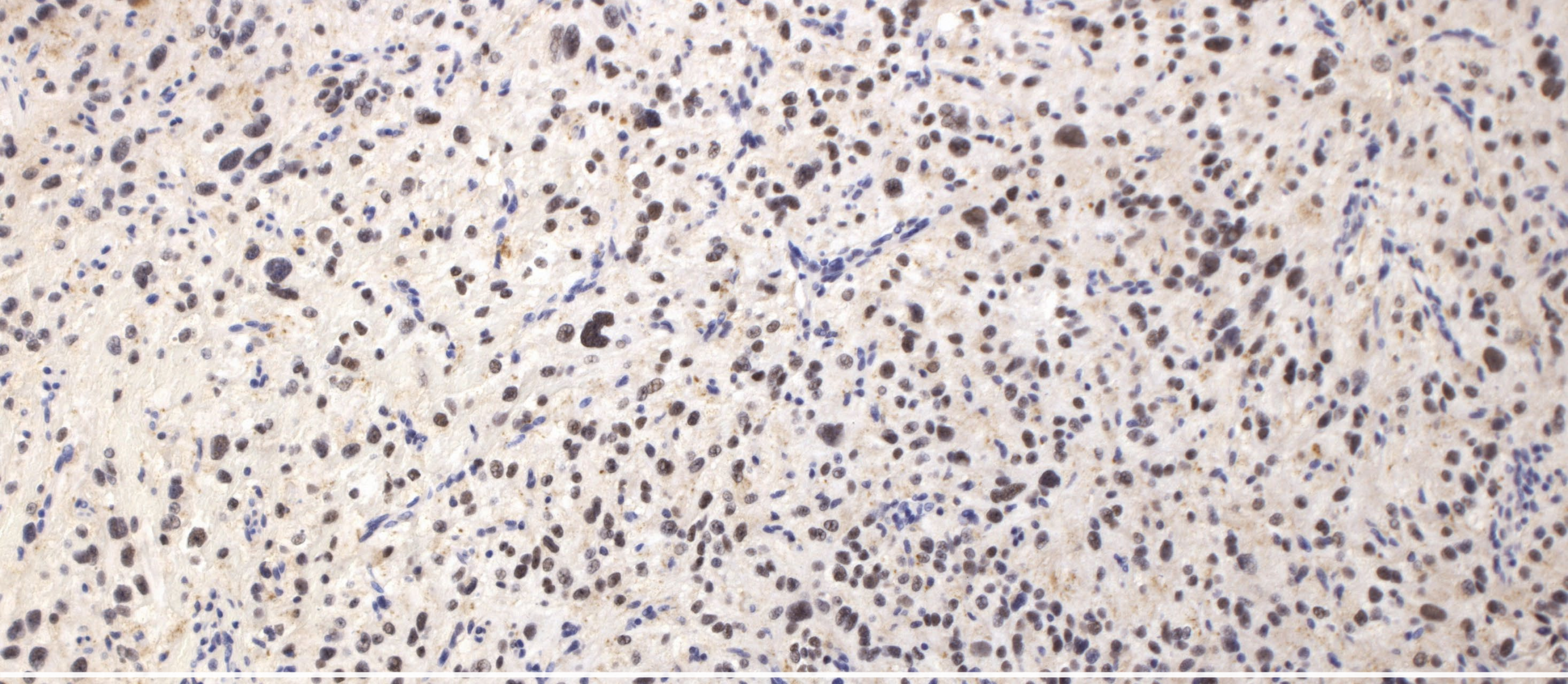
IDH1 R132



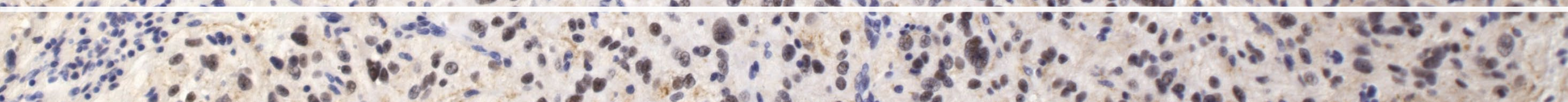


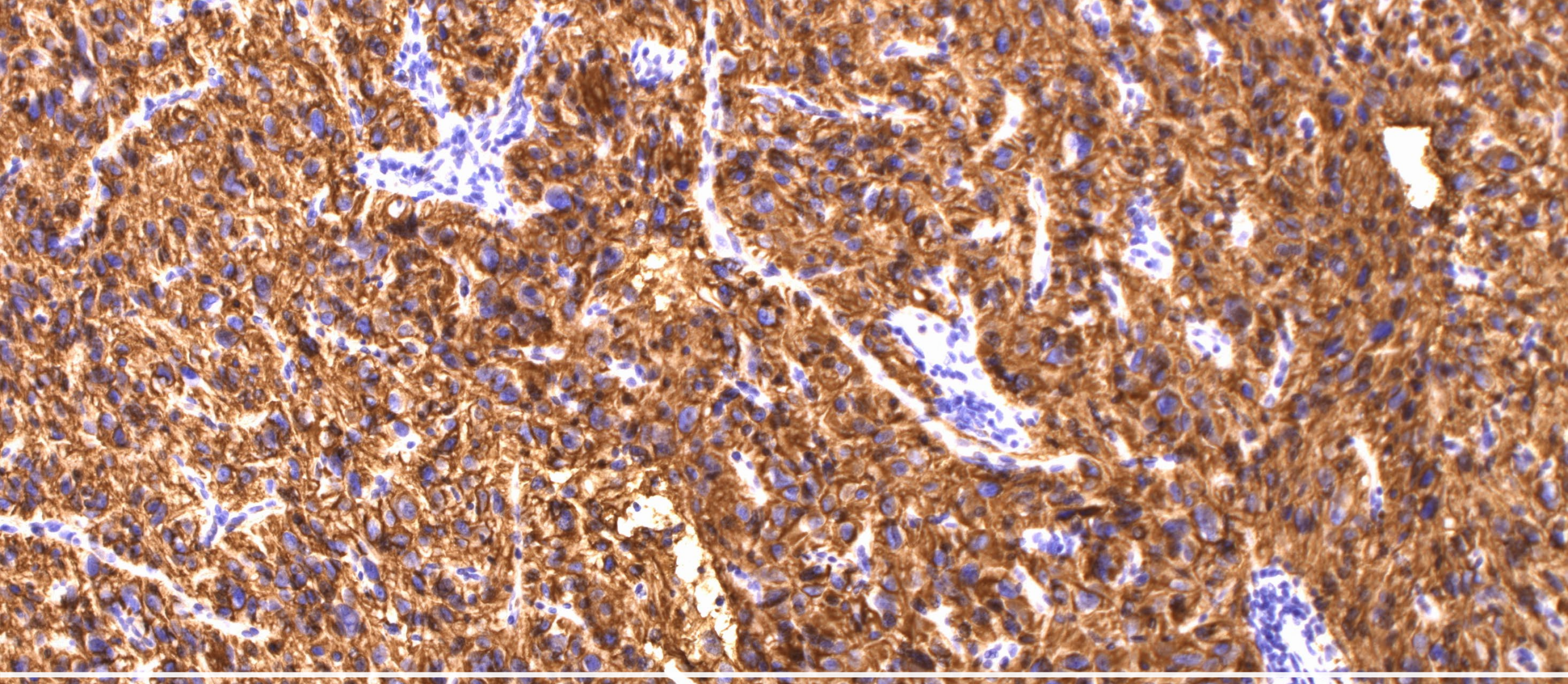
p53



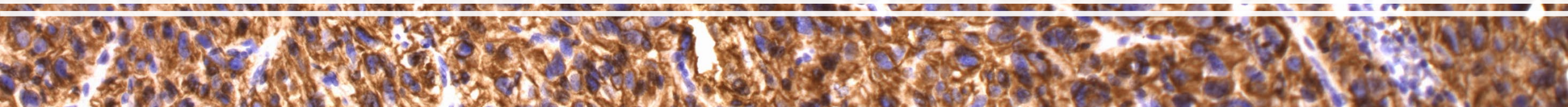


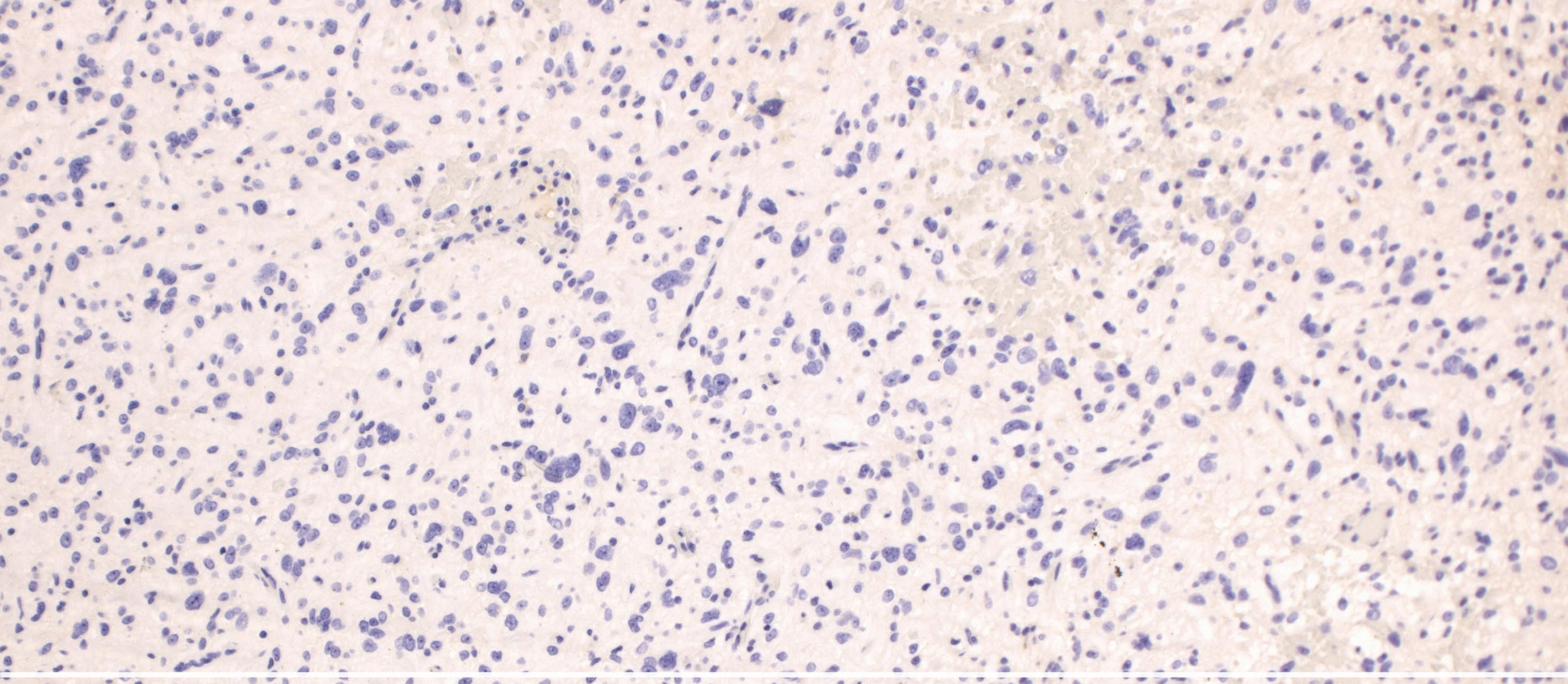
ATRX



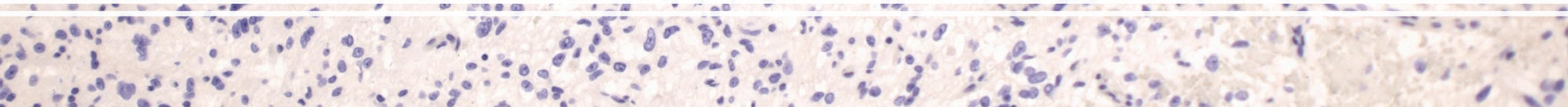


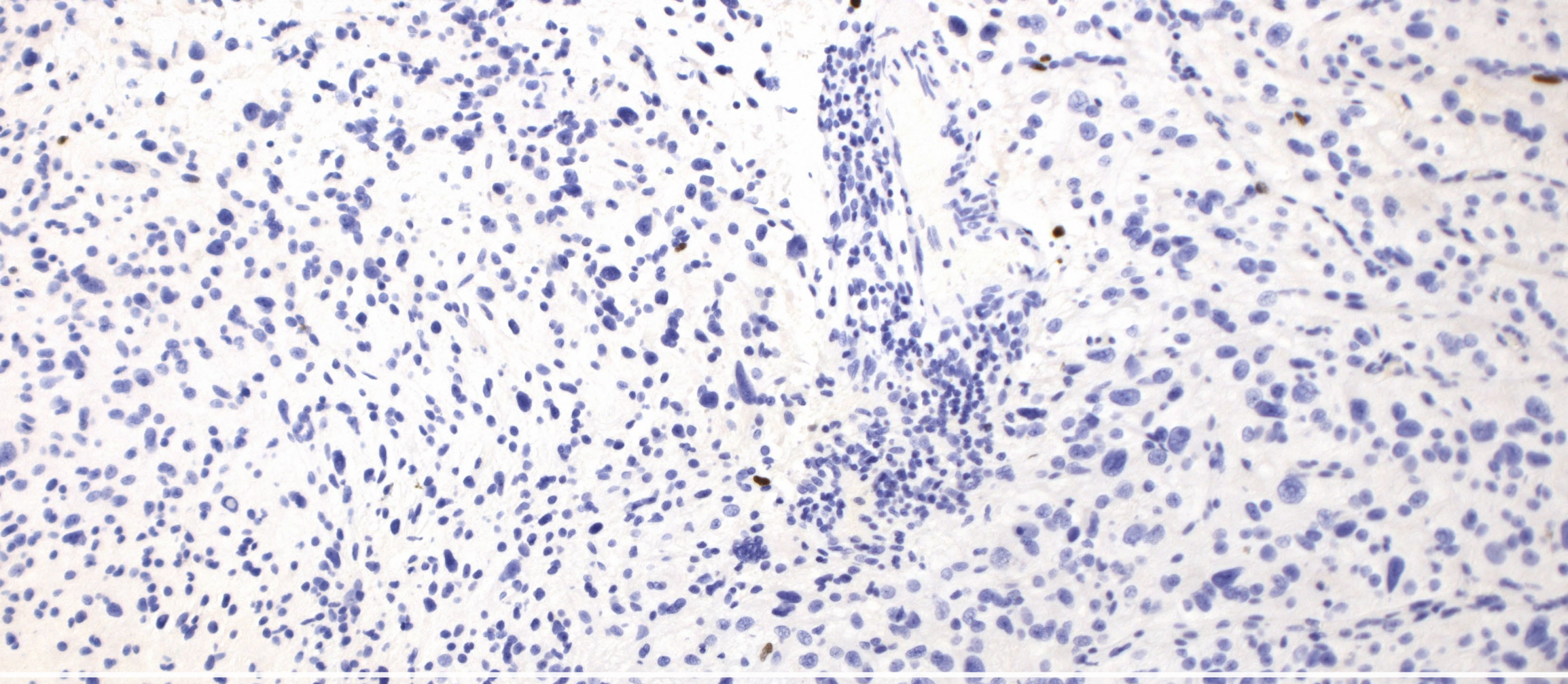
CD34



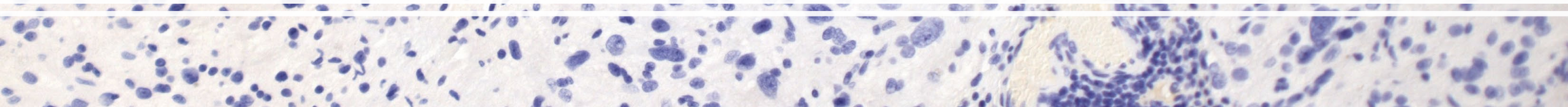


EMA





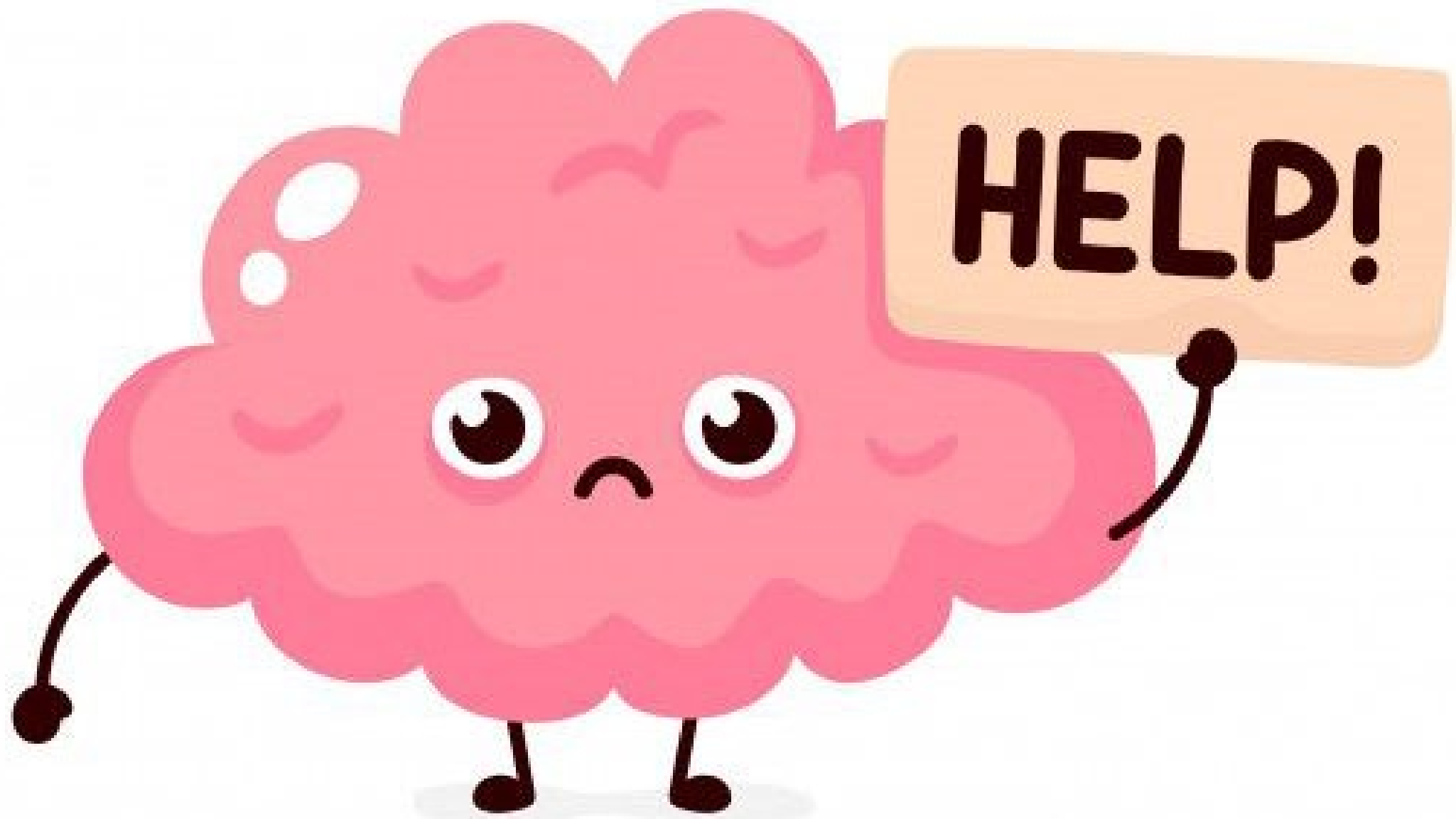Ki-67



Genetické vyšetření

- PCR sekvenace genů *IDH1/2* – negativní, IDH wildtype
- FISH vyšetření kodelece 1p/19q – bez průkazné kodelece
- PCR mutační analýza genu *BRAF* – průkaz aktivační mutace *BRAF V600*

Přehled IHC	
Pozitivní markery	Negativní markry
GFAP	EMA
OLIG2	IDH1
CD34	Wildtype exprese p53 a ATRX
	Neu-N
	Synaptophysin



HELP!

PLNTY – polymorfní low-grade neuroepiteliální tumor mladých

WHO CNS 2021 – grade 1

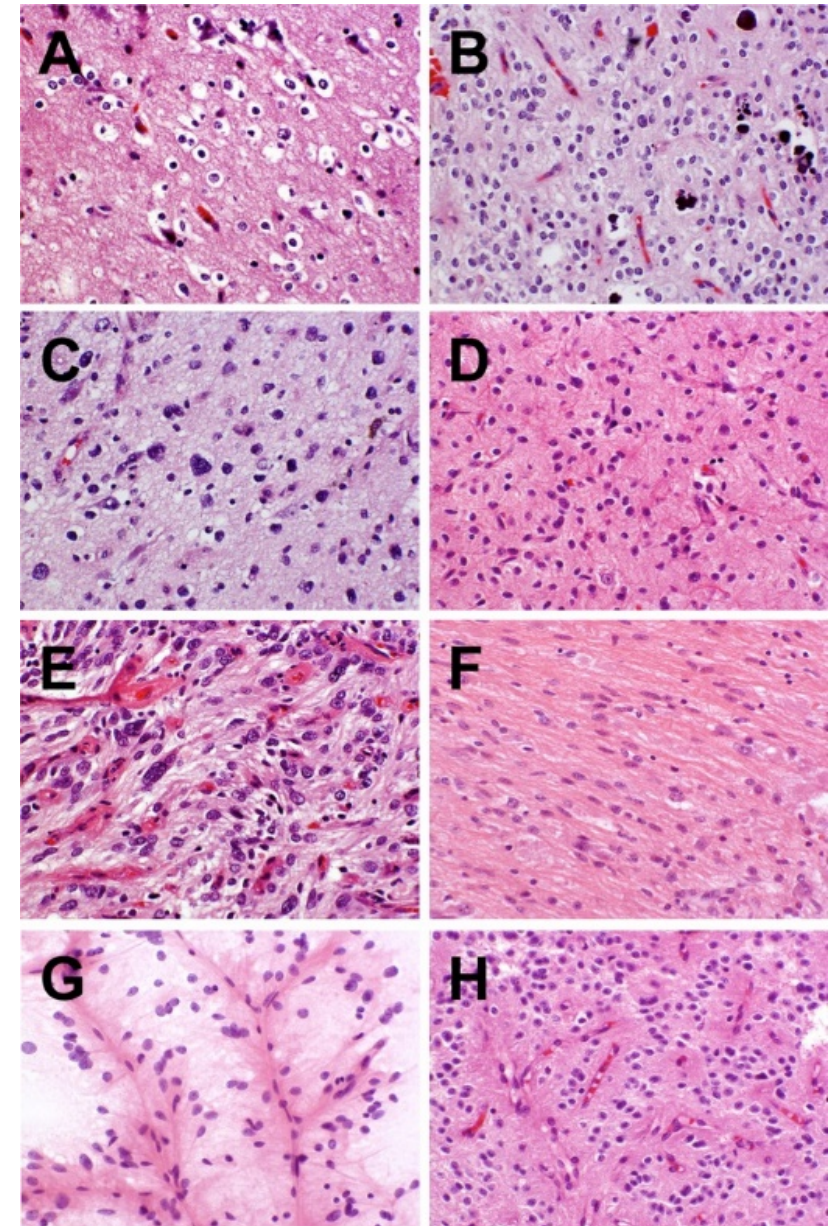
PLNTY – polymorfní low-grade neuroepiteliální tumor mladých

> *Acta Neuropathol.* 2017 Mar;133(3):417-429. doi: 10.1007/s00401-016-1639-9. Epub 2016 Nov 3.

Polymorphous low-grade neuroepithelial tumor of the young (PLNTY): an epileptogenic neoplasm with oligodendroglioma-like components, aberrant CD34 expression, and genetic alterations involving the MAP kinase pathway

Jason T Huse¹, Matija Snuderl², David T W Jones³, Carole D Brathwaite⁴, Nolan Altman⁵, Ehud Lavi⁶, Richard Saffery⁷, Alexandra Sexton-Oates⁷, Ingmar Blumcke⁸, David Capper⁹, Matthias A Karajannis^{10 11}, Ryma Benayed¹², Lukas Chavez³, Cheddi Thomas², Jonathan Serrano², Laetitia Borsu¹², Marc Ladanyi¹², Marc K Rosenblum¹²

Morphological features of PLNTY. Oligodendroglial (a, b), fibrillary astrocytic (c, d), and spindled astrocytic (e, f) features as seen in cases 3 (a, c, e) and 6 (b, d, f). Vague perivascular pseudorosetting (g, h) as seen in case 5 by smear preparation (g) as well as sectioning (h)



PLNTY – polymorfní low-grade neuroepiteliální tumor mladých – genetické alterace

- Dysregulace v MAP kinázové signální kaskádě
 - Alterace genu *BRAF*, *FGFR2*, *FGFR3* a *NTRK2*

Chen *et al.* *BMC Neurology* (2020) 20:123
<https://doi.org/10.1186/s12883-020-01679-3>

BMC Neurology

CASE REPORT

Open Access

Polymorphous low-grade neuroepithelial tumor of the young: case report and review focus on the radiological features and genetic alterations



Yingqian Chen^{1†}, Tian Tian^{2†}, Xinwen Guo³, Fenfen Zhang², Miao Fan¹, Huawei Jin^{4*} and Dawei Liu^{2*}

WHO CNS 2021

The 2021 WHO Classification of Tumors of the Central Nervous System: a summary

David N. Louis, Arie Perry, Pieter Wesseling^o, Daniel J. Brat^o, Ian A. Cree, Dominique Figarella-Branger, Cynthia Hawkins, H. K. Ng, Stefan M. Pfister, Guido Reifenberger, Riccardo Soffietti, Andreas von Deimling, and David W. Ellison

World Health Organization Classification of Tumors of the Central Nervous System, fifth edition

Gliomas, glioneuronal tumors, and neuronal tumors

Adult-type diffuse gliomas

Astrocytoma, IDH-mutant

Oligodendroglioma, IDH-mutant, and 1p/19q-codeleted

Glioblastoma, IDH-wildtype

Pediatric-type diffuse low-grade gliomas

Diffuse astrocytoma, *MYB*- or *MYBL1*-altered

Angiocentric glioma

Polymorphous low-grade neuroepithelial tumor of the young

Diffuse low-grade glioma, MAPK pathway altered

Pediatric-type diffuse high-grade gliomas

Diffuse midline glioma, H3 K27-altered

Diffuse hemispheric glioma, H3 G34-mutant

Diffuse pediatric-type high-grade glioma, H3-wildtype and IDH-wildtype

Infant-type hemispheric glioma

Circumscribed astrocytic gliomas

Pilocytic astrocytoma

High-grade astrocytoma with piloid features

Pleomorphic xanthoastrocytoma

Subependymal giant cell astrocytoma

Chordoid glioma

Astroblastoma, *MN1*-altered

Biologické chování

- WHO CNS 2021 – grade 1
- Kazuistika popisující progresi v GBM
 - PLNTY s fúzí *FGFR3-TACC3*

› [Acta Neuropathol.](#) 2021 Jan;141(1):123-125. doi: 10.1007/s00401-020-02245-4. Epub 2020 Nov 23.

Malignant transformation of a polymorphous low grade neuroepithelial tumor of the young (PLNTY)

Tejus A Bale ^{# 1}, Sameer F Sait ^{# 2}, Jamal Benhamida ³, Ryan Ptashkin ³, Sofia Haque ⁴, Liliana Villafania ³, Martin Sill ^{5 6}, Justyna Sadowska ³, Razia B Akhtar ⁷, Benjamin Liechty ⁸, Rupa Juthani ^{9 10}, Marc Ladanyi ^{3 9}, Mary Fowkes ¹¹, Matthias A Karajannis ^{# 2}, Marc K Rosenblum ^{# 3}

Affiliations [+](#) expand

PMID: 33226472 DOI: [10.1007/s00401-020-02245-4](#)

Dif. dg.

- Difúzní gliomy
 - Oligodendrogliom, IDH-mutovaný s kodelecí 1p/19q
 - Oligoastrocytom NOS
 - Difúzní astrocytom, IDH-wildtype

- LEATs
 - Gangliogliom
 - Pilocytární astrocytom

**MUNI
MED**

FAKULTNÍ
NEMOCNICE
U SV. ANNY
V BRNĚ



Děkuji za pozornost